


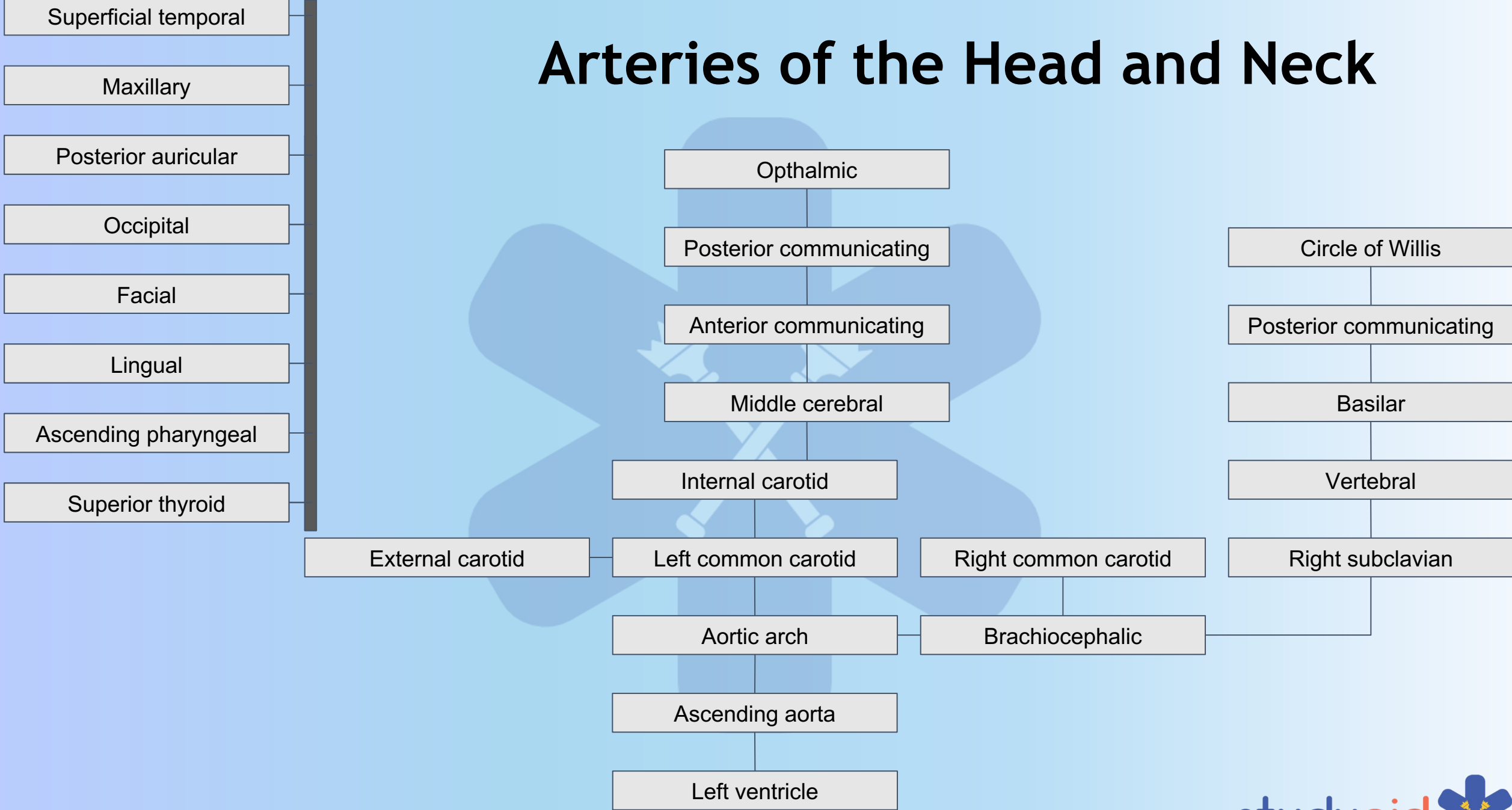
Head and Neck Blood Supply

By Josefine Holum

Arteries of the Head and Neck



Arteries of the Head and Neck



Arteries of the Head and Neck

Superficial temporal

Maxillary

Posterior auricular

Occipital

Facial

Lingual

Ascending pharyngeal

Superior thyroid

Ophthalmic

Posterior communicating

Anterior communicating

Middle cerebral

Internal carotid

Left common carotid

Right common carotid

Aortic arch

Brachiocephalic

Ascending aorta

Left ventricle

Circle of Willis

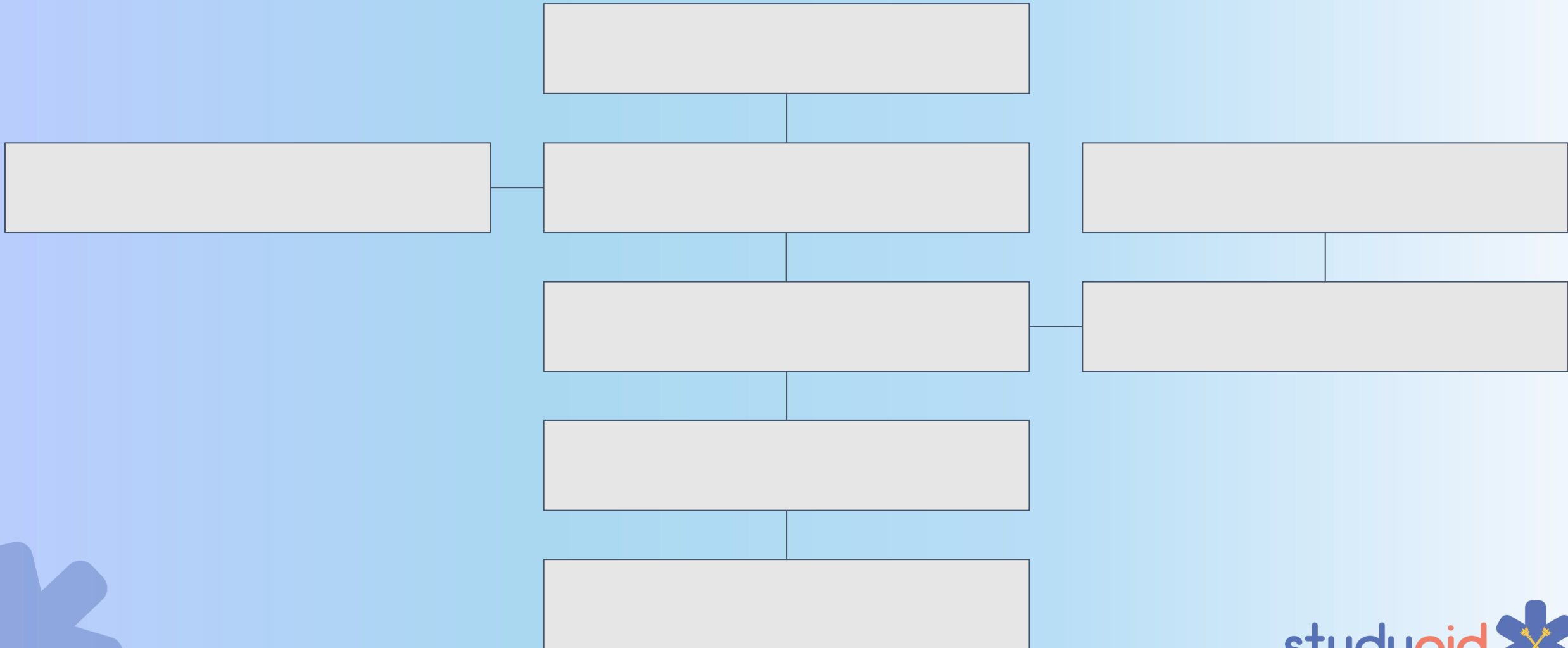
Posterior communicating

Vertebral

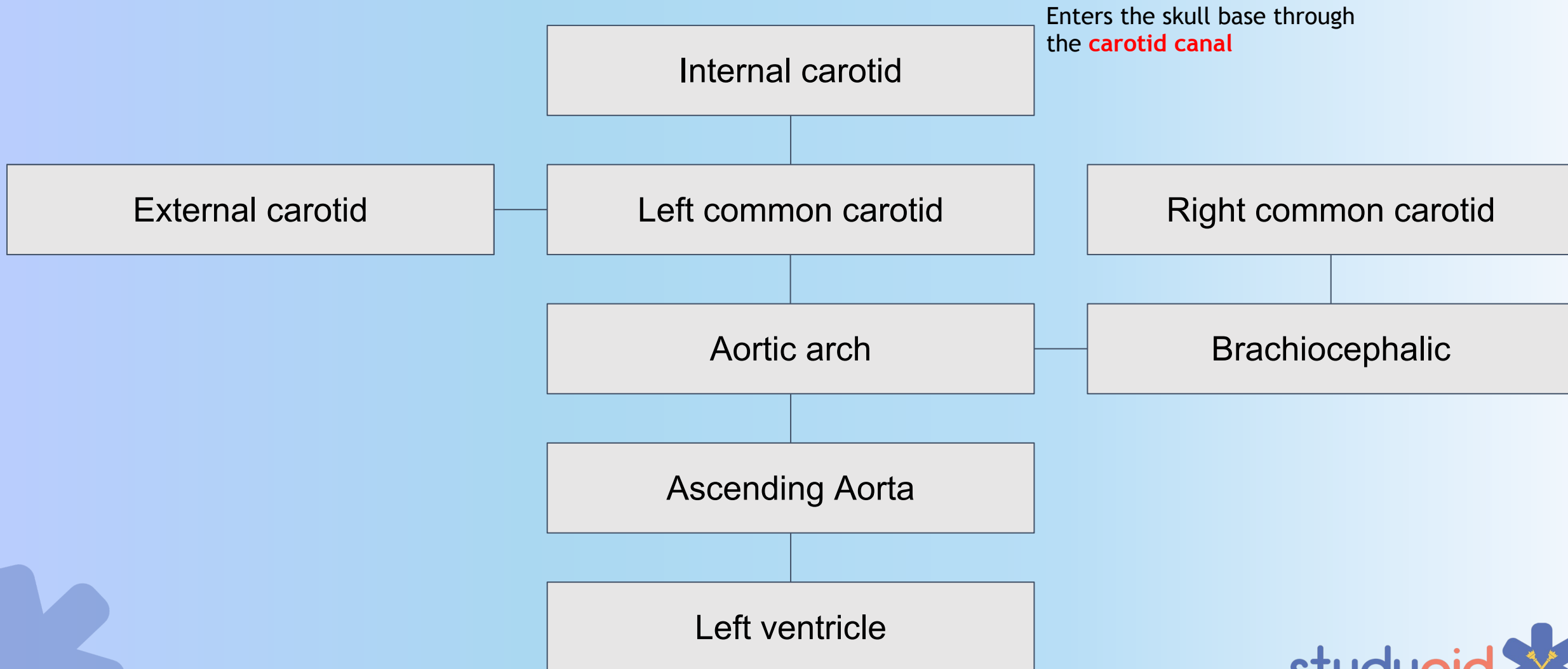
Right subclavian

External carotid

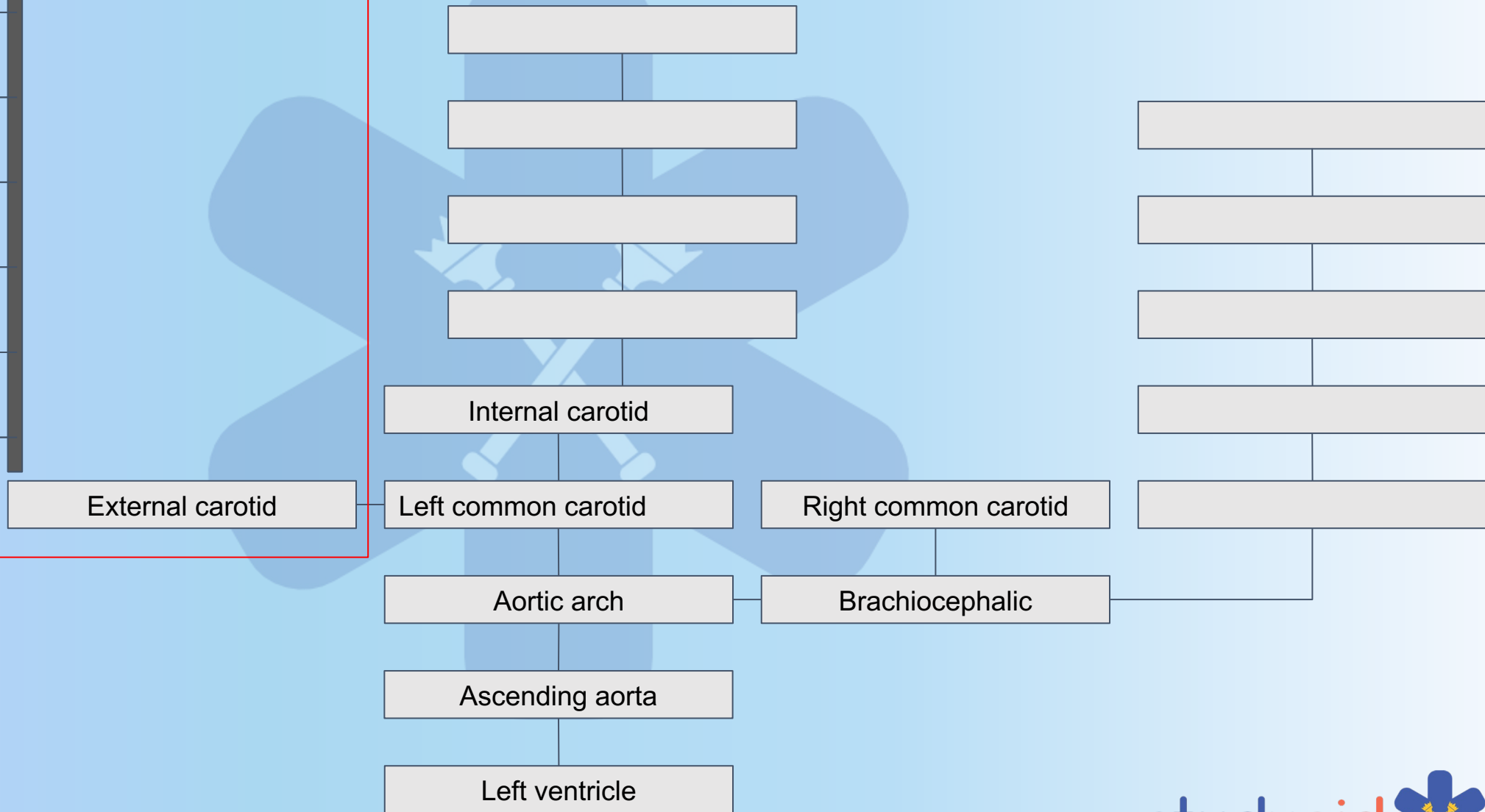
Arteries of the Head and Neck



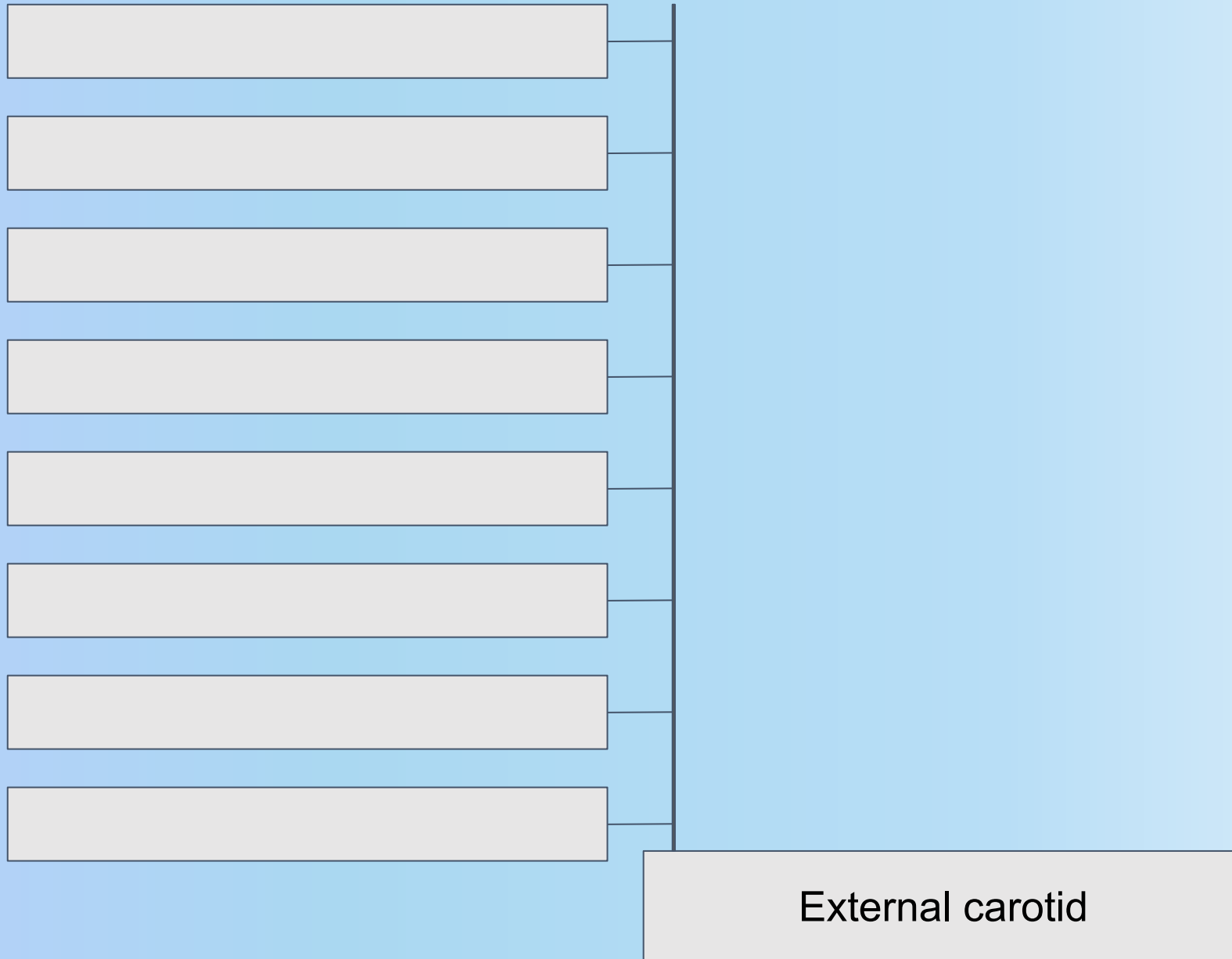
Arteries of the Head and Neck



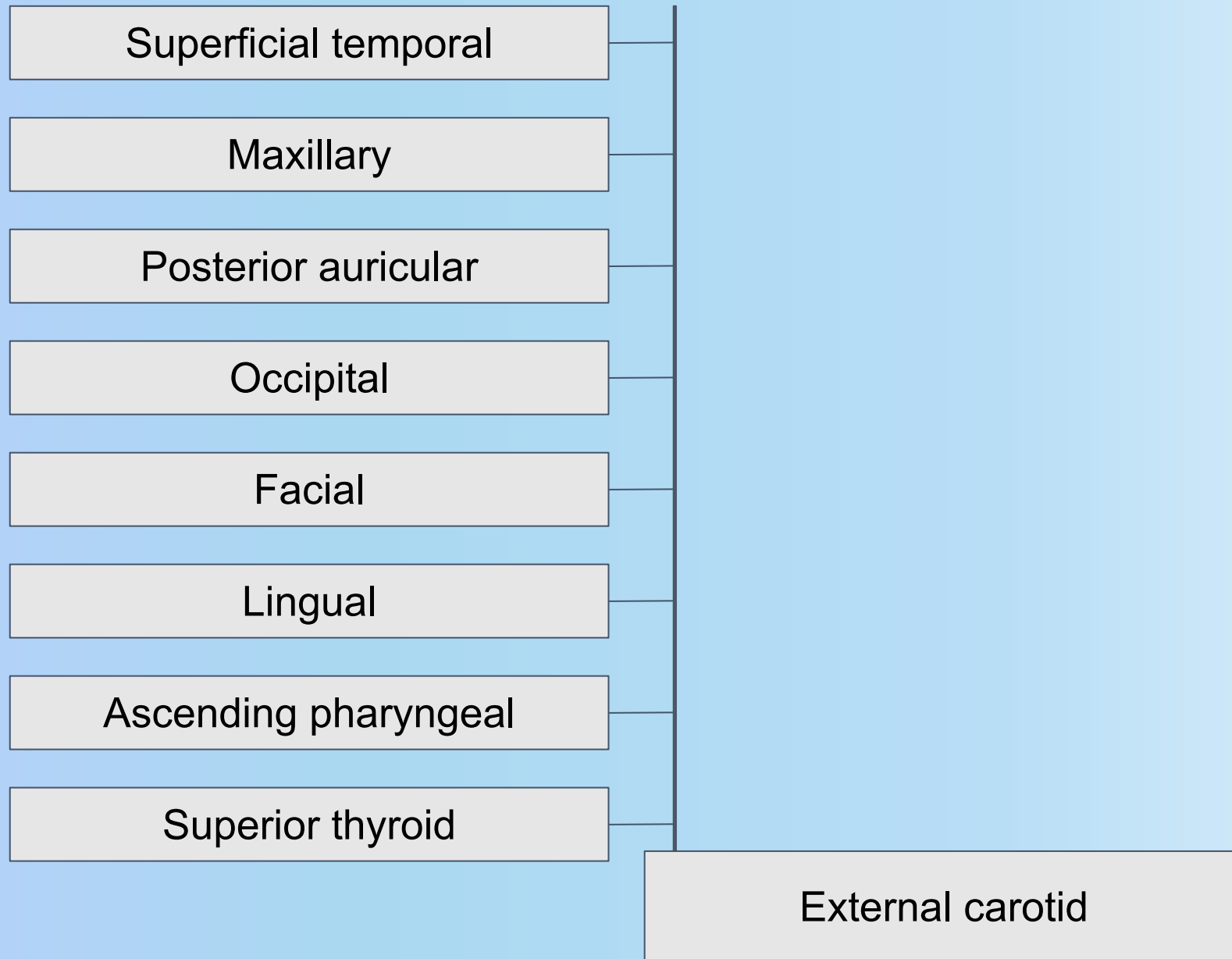
Arteries of the Head and Neck



Arteries of the Head and Neck



Arteries of the Head and Neck



MNEMONIC = SALFOPMS

S - superior thyroid

A - ascending pharyngeal

L - lingual

F - facial

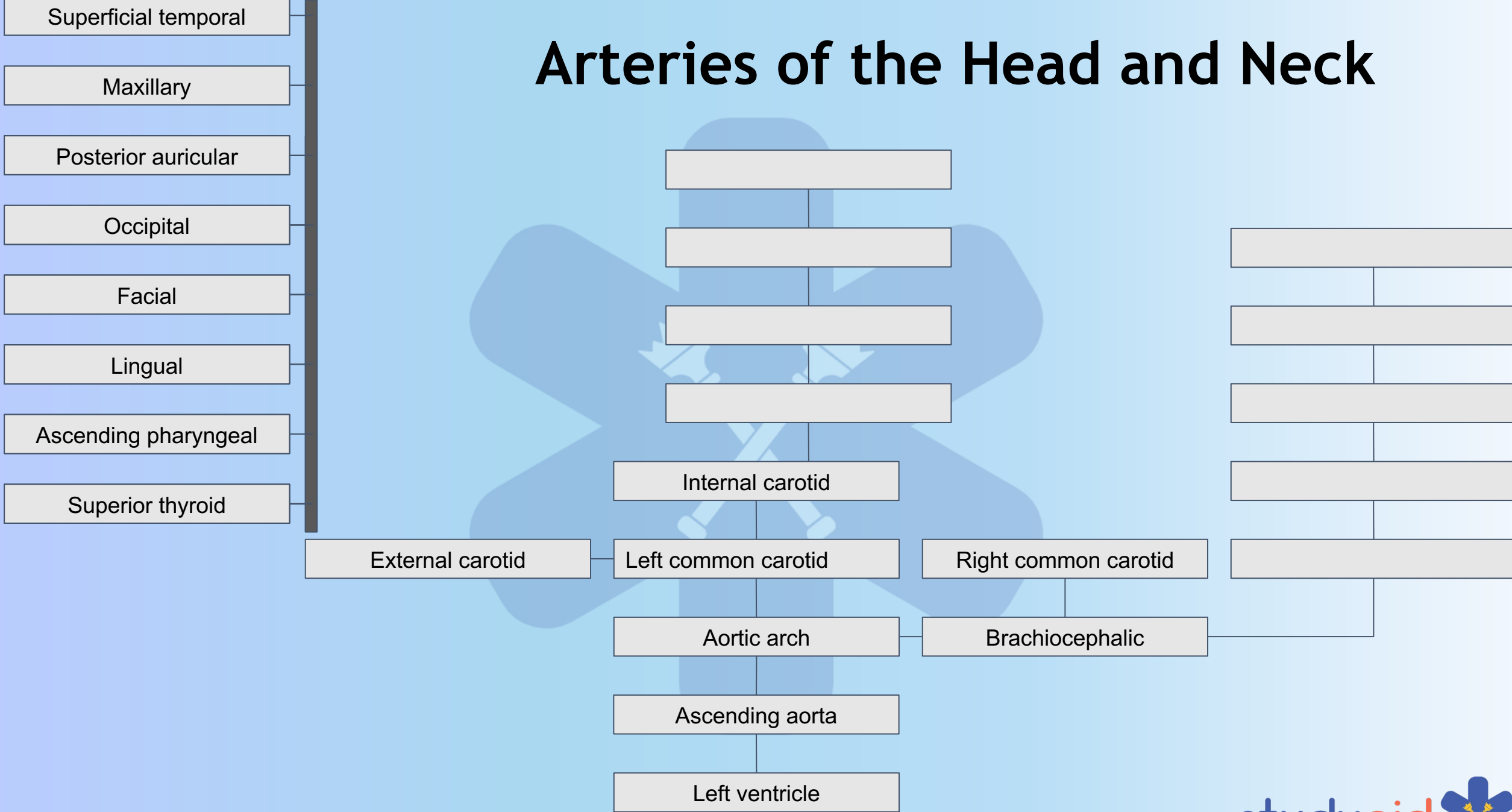
O - occipital

P - posterior auricular

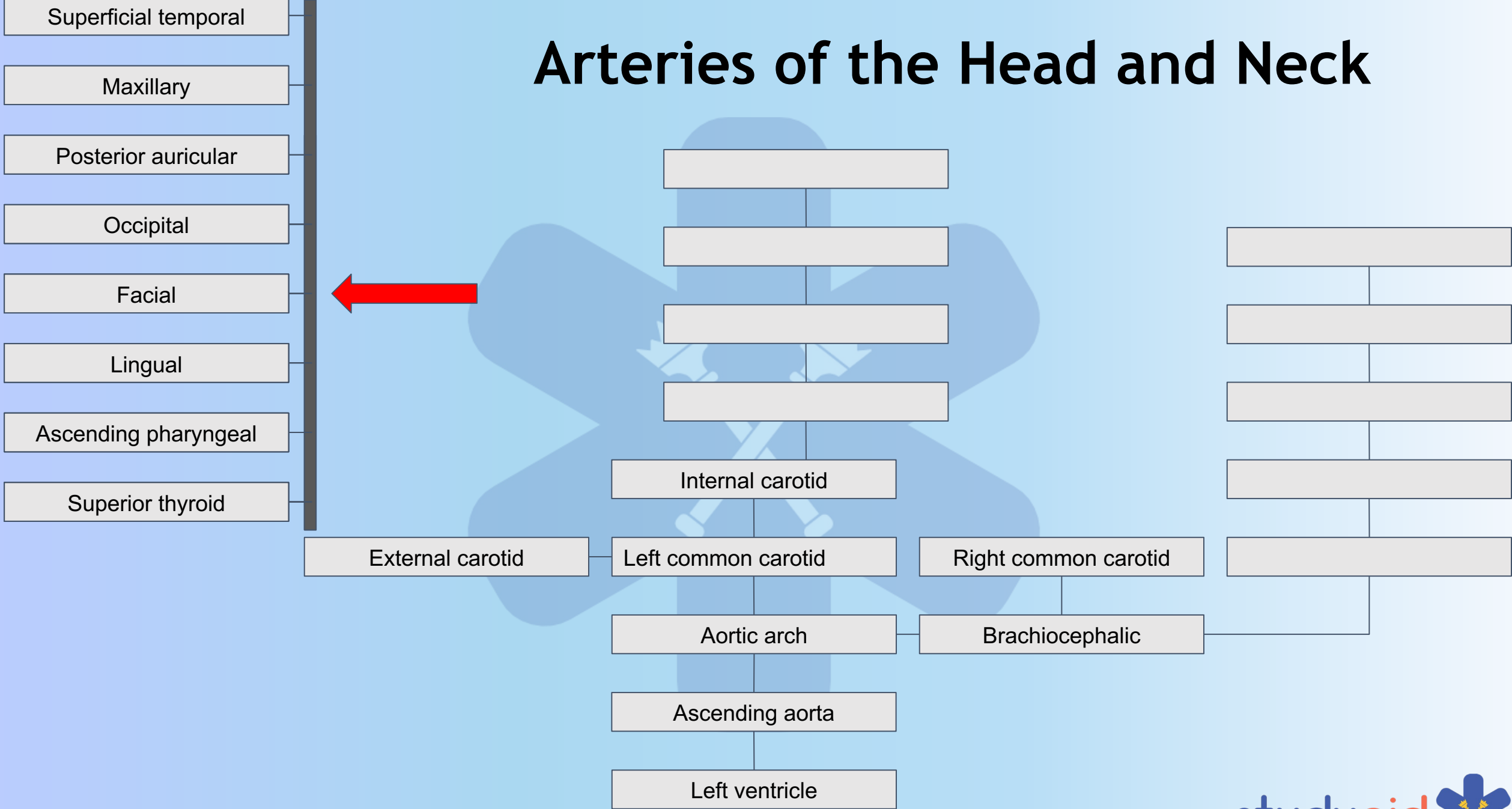
M - maxillary

S - superficial temporal

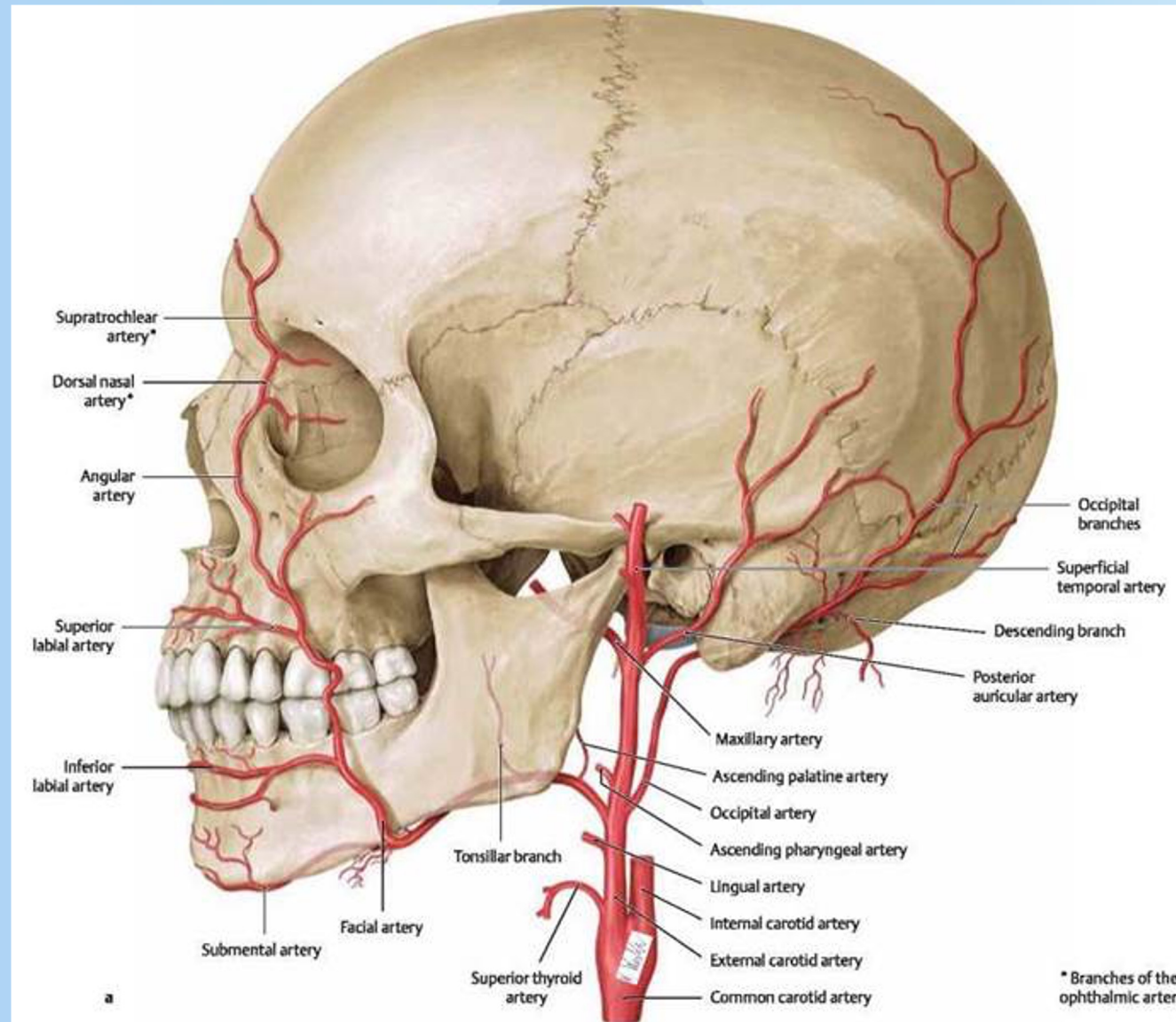
Arteries of the Head and Neck




Arteries of the Head and Neck



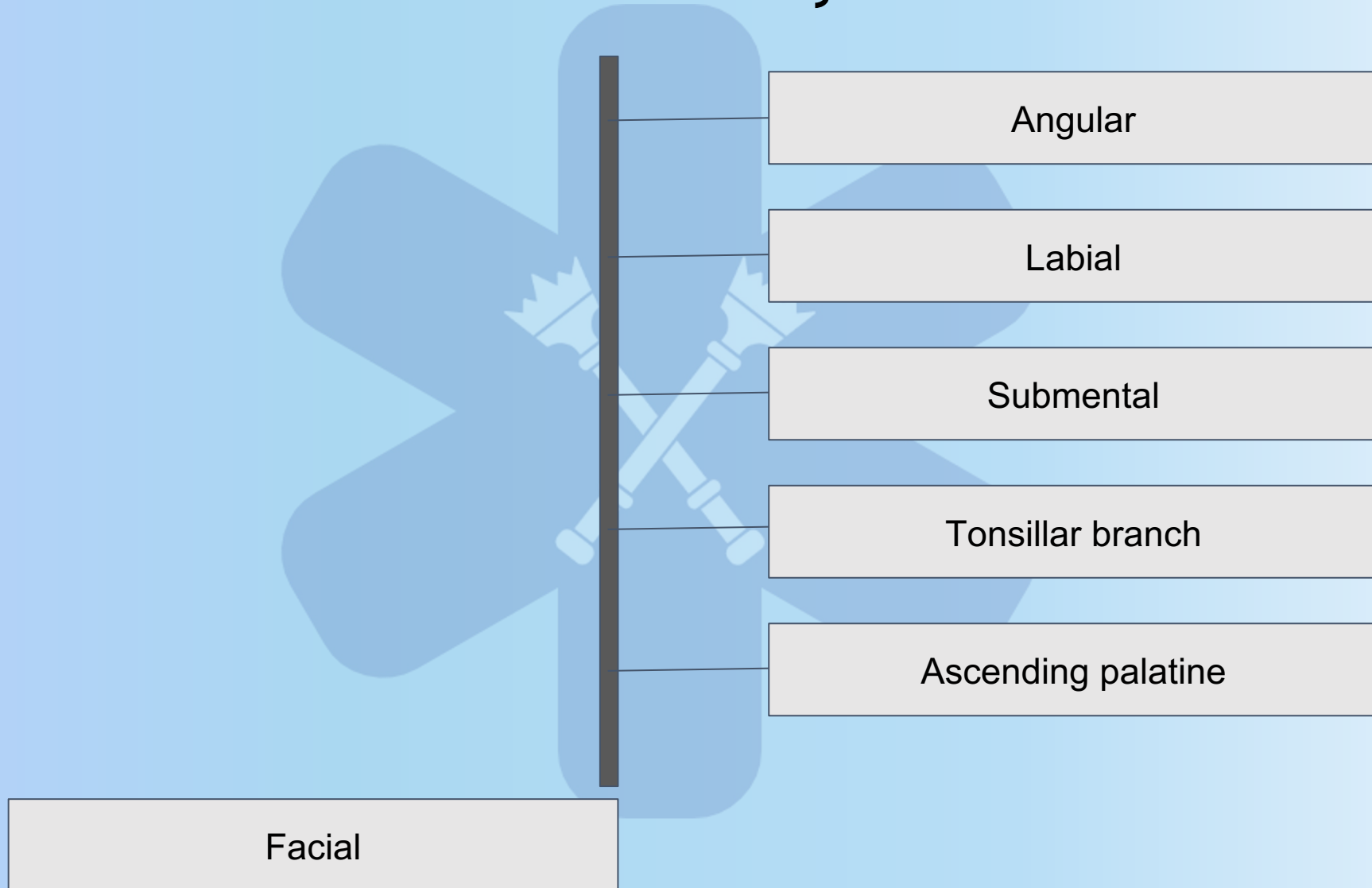
Facial Artery



Facial Artery



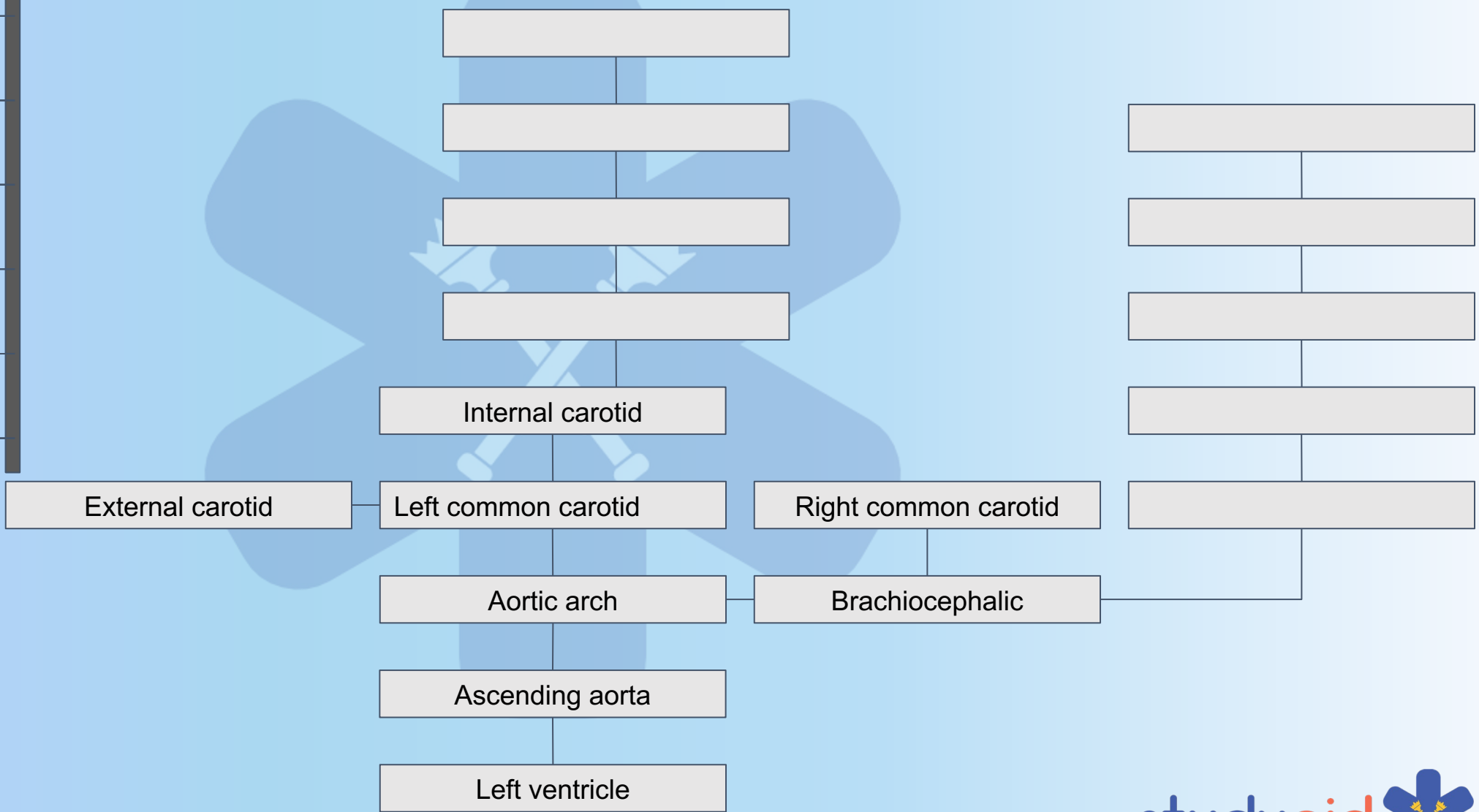
Facial Artery



Arteries of the Head and Neck



- Superficial temporal
- Maxillary
- Posterior auricular
- Occipital
- Facial
- Lingual
- Ascending pharyngeal
- Superior thyroid



Maxillary Artery

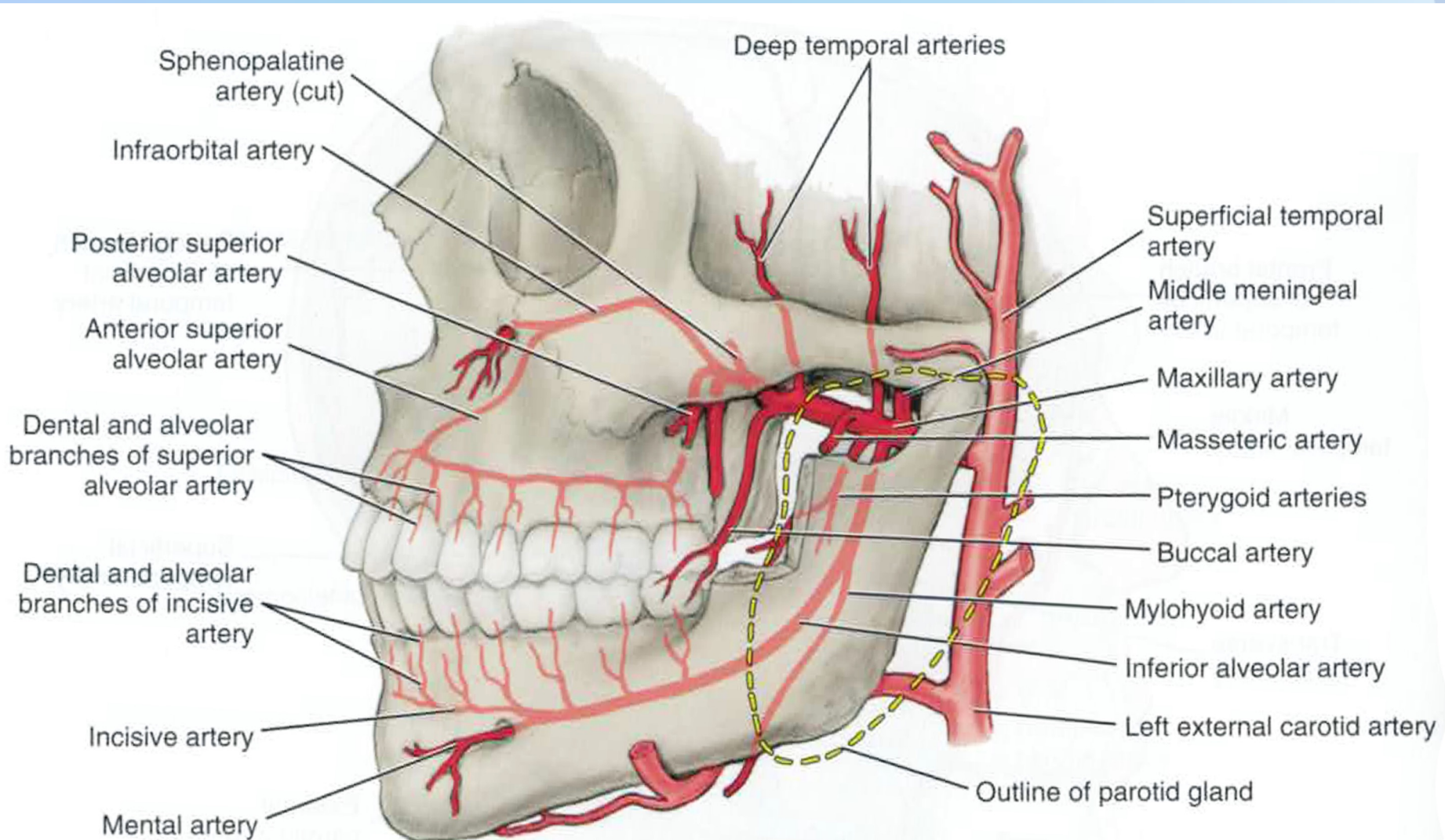
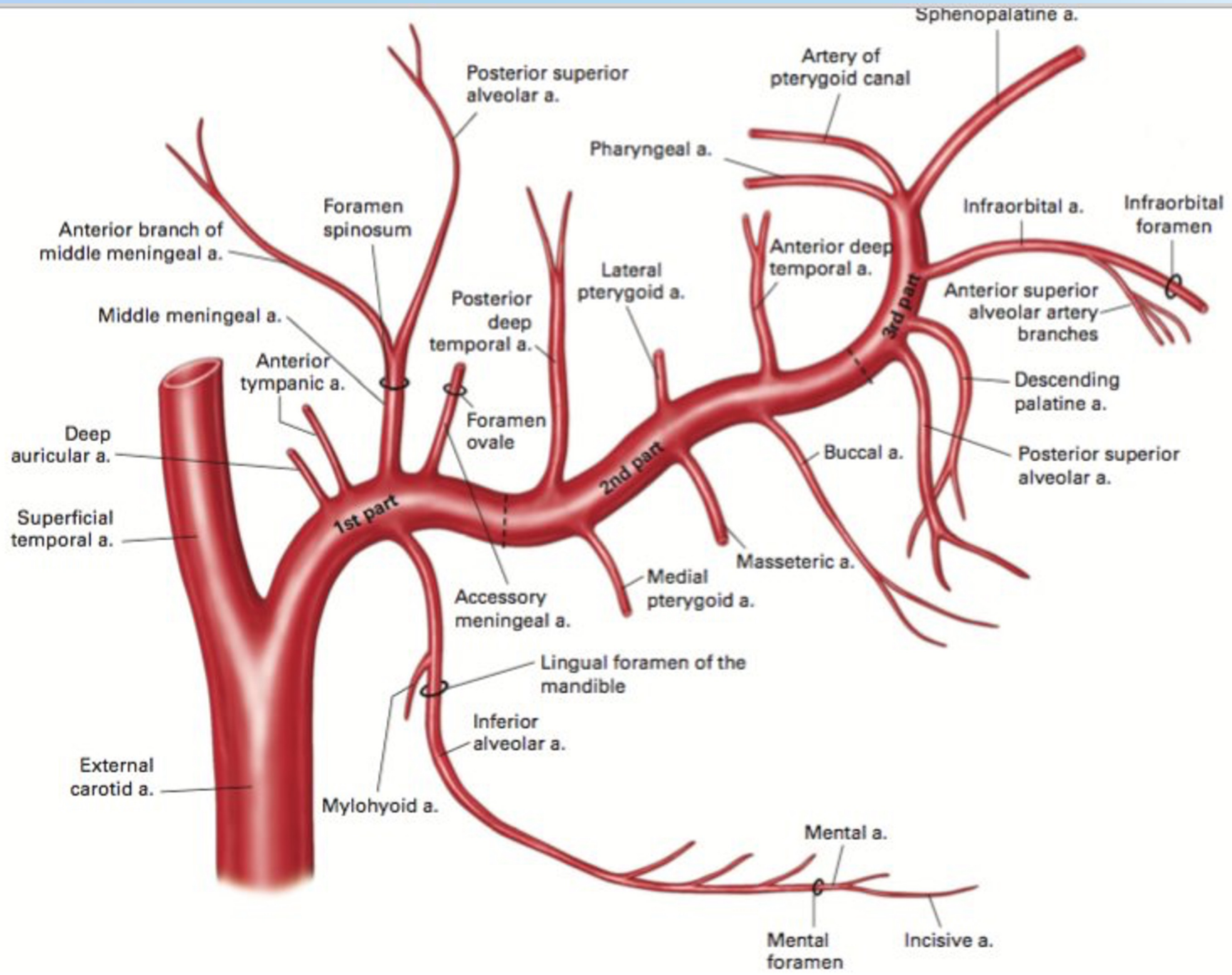


FIGURE 6-9 Pathway of the maxillary artery (except those branches to nasal cavity and palate).



Retromandibular fossa

Infratemporal fossa

Pterygopalatine fossa

Retromandibular fossa

Deep auricular

Anterior tympanic

Middle meningeal

Inferior alveolar

Accessory meningeal

Infratemporal fossa

Deep temporal

Masseteric

Pterygoid branches

Buccinator

Pterygopalatine fossa

Sphenopalatine

Descending palatine

Infraorbital

Posterior superior alveolar

Middle superior alveolar

Pharyngeal

Anterior superior alveolar

Artery of the pterygoid canal

MNEMONIC

DAM I AM **Piss Drunk But Stupid Drunk I Prefer**, **Must Call Alcoholic Anonymous**

D - deep auricular

A - anterior tympanic

M - middle meningeal

I - inferior alveolar

A - accessory meningeal

M - masseteric

P - pterygoid

D - deep temporal

B - buccinator

S - sphenopalatine

D - descending palatine

I - infraorbital

P - posterior superior alveolar

M - middle superior alveolar

P - pharyngeal

A - anterior superior alveolar

A - artery of the pterygoid canal

MNEMONIC

DAM I AM Piss Drunk But Stupid Drunk I Prefer, Must Call Alcoholic Anonymous

D - deep auricular

A - anterior tympanic

M - middle meningeal

I - inferior alveolar

A - accessory meningeal

M - masseteric

P - pterygoid

D - deep temporal

B - buccinator

S - sphenopalatine

D - descending palatine

I - infraorbital

P - posterior superior alveolar

M - middle superior alveolar

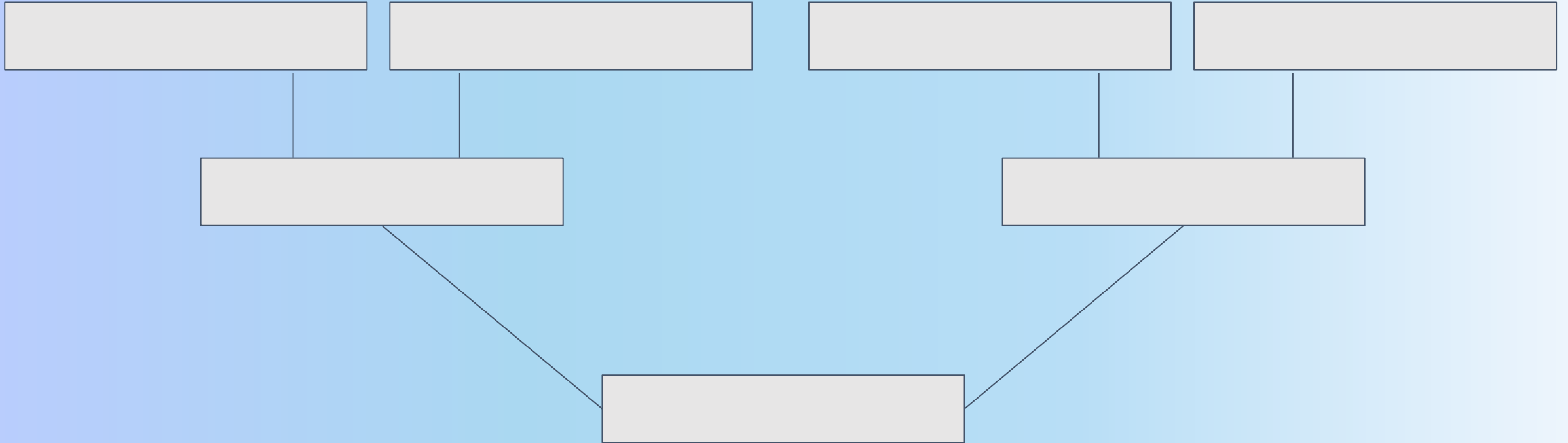
P - pharyngeal

A - anterior superior alveolar

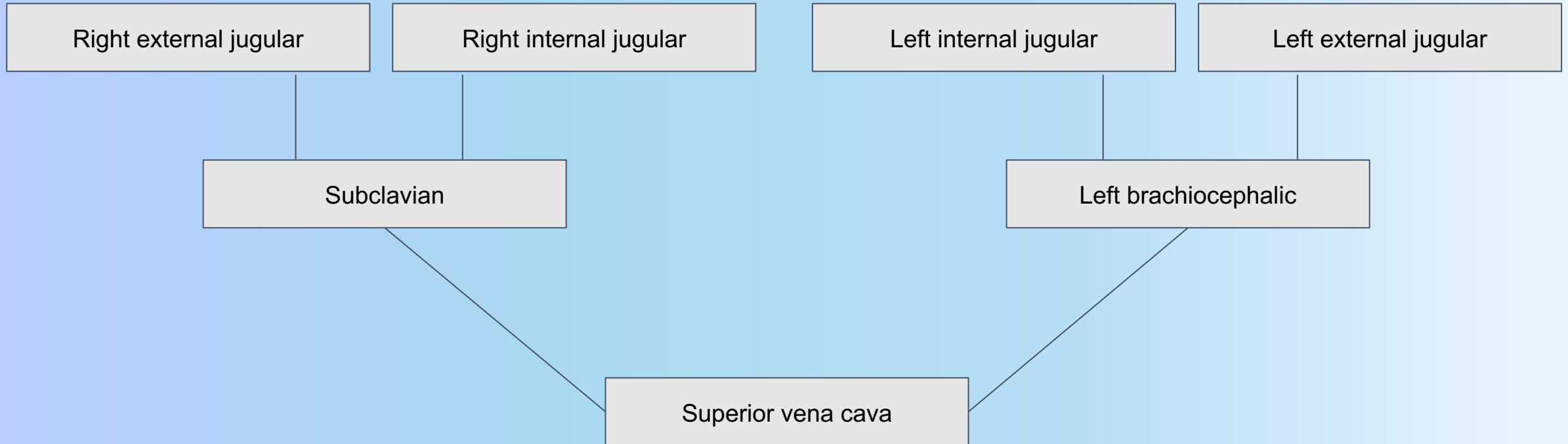
A - artery of the pterygoid canal

5 - 4 - 8

Veins of the Head and Neck



Veins of the Head and Neck



QUESTIONS?